

DOI: <https://doi.org/10.57231/j.ao.2024.7.1.006>

УДК: 616.716.78/3-001-06-079.1-08]616.8

## THE EFFICIENCY OF OPHTHALMIC DIAGNOSTICS IN THE TREATMENT CRANIOORBITAL DAMAGE

Mirbabayeva F.A.

PhD, Associate Professor of the Department of Ophthalmology, Tashkent State Dental Institute, mirbabaevaferuza@gmail.com, +998(90)970-05-00, <https://orcid.org/0000-0002-4568-4691>

**Annotation. Relevance.** Fractures of the zygomatico-orbital complex are the second most common injury after fractures of the mandible. They account for 16-25% of all injuries to the maxillofacial area and correspond to general trends in injury: a constant increase in the number of victims, an increase in complex types of fractures, a rejuvenation of the patient population, and aggravation of injury due to its compatibility. **The purpose of the study.** To study visual function of disorders in patients with orbital wall fracture depending on their localization. **Material and methods.** Analysis of a comprehensive clinical examination of 62 patients aged 16 to 60 years, with craniorbital injury, who were on inpatient treatment in the departments of Maxillofacial surgery of the dental clinic of the Tashkent State Dental Institute and 2 clinics of the Tashkent medical Academy were studied. **Results and conclusion.** A comprehensive survey of patients allowed us to exclude the presence of pathology of the organ of vision trauma of the orbit, combined with traumatic brain injury of mild severity, which should ensure an objective approach in qualifying the severity of the injury. Reconstructive operations in the early period of craniocerebral trauma can achieve regression of oculomotor disorders in 98.4%, dystopia of the eyeball-in 82.5%, diplopia-in 86.5% and get good cosmetic outcomes.

**Keywords:** orbital trauma, reconstructive surgery, severity of injury.

### For citation:

Mirbabayeva F.A. The efficiency of ophthalmic diagnostics in the treatment craniorbital damage. *Advanced ophthalmology.* 2024;7(1):37-41.

## КРАНИООРБИТАЛЬНЫЕ ПОВРЕЖДЕНИЯ И ВЛИЯНИЕ ИХ НА ПОКАЗАТЕЛИ ЗРИТЕЛЬНЫХ ФУНКЦИЙ

Мирбабаева Ф.А.<sup>1</sup>

1. Кандидат медицинских наук, доцент кафедры Офтальмологии, Ташкентский государственный стоматологический институт, e-mail: mirbabaevaferuza@gmail.com, +998(90)970-05-00, <https://orcid.org/0000-0002-4568-4691>

**Аннотация. Актуальность.** Переломы скуло-орбитального комплекса занимают второе место по частоте возникновения повреждения после переломов нижней челюсти. Они составляют от 16-25% от всех травм челюстно-лицевой области и отвечают общим тенденциям травматизма: постоянное увеличение числа пострадавших, рост сложных типов переломов, омоложение контингента больных, утяжеление травмы за счет ее сочетаемости. **Цель исследования.** Изучить нарушения зрительной функции у больных с переломом стенок орбиты в зависимости от их локализации. **Материал и методы.** За период 2020-2023 гг. изучен анализ комплексного клинического обследования 62 пациента в возрасте от 16 до 60 лет, с краниоорбитальным повреждением, находившихся на стационарном лечении в отделениях Челюстно – лицевой хирургии стоматологической клиники Ташкентского государственного стоматологического института и 2- клиники Ташкентской медицинской академии. **Результаты и обсуждения.** Комплексное обследование пациентов позволило исключить наличие патологии органа зрения при травме орбиты, сочетанной с ЧМТ легкой степени тяжести, что должно обеспечить объективный подход в квалификации степени тяжести вреда здоровью. Проведение реконструктивных операций в раннем периоде краниоорбитальной травмы позволяет добиться регресса глазодвигательных нарушений в 98,4%, дистопии глазного яблока – в 82,5%, диплопии – в 86,5% и получить хорошие косметические исходы.

**Ключевые слова:** орбитальная травма, реконструктивная хирургия, степень тяжести вреда здоровью.

### Для цитирования:

Мирбабаева Ф.А. Краниоорбитальные повреждения и влияние их на показатели зрительных функций.- *Передовая офтальмология.* 2024;7(1):37-41.

## KRANIOORBITAL SHIKASTLANISHLAR VA ULARNING KO'RUV FAOLIYATLARIGA TA'SIRI

Mirbabaeva F.A.

Тиббиёт фанлари номзоди, Офтальмология кафедраси доценти, Тошкент давлат стоматология институти, mirbabaevaferuza@gmail.com, +998(90)970-05-00, <https://orcid.org/0000-0002-4568-4691>

**Annotatsiya. Dolzarbliqi.** Yonoq-orbital kompleksning sinishi pastki jag'ning sinishidan keyin shikastlanish chastotasi bo'yicha ikkinchi o'rinda turadi. Ular yuz-jag' sohasidagi barcha jarohatlarning 16-25% ni tashkil qiladi va jarohatlarning umumiy tendentsiyalariga javob beradi: jaroxatlanganlar sonining doimiy o'sishi, murakkab sinish turlarining ko'payishi, bemorlar kontingentini yosharshi, shikaastlanishning kombinirlangan kelishi natijasida uning og'irlik darajasini oshishi. **Tadqiqot maqsadi.** Ko'z kosasi devorlari singan bemorlarda, ularning lokalizatsiyasiga qarab, ko'ruv faoliyatini buzilishini o'rganish. **Materiallar va usullar.** 2020-2023 yillar davrida Toshkent davlat stomatologiya instituti stomatologiya klinikasining yuz – jag' jarroxligi bo'limlarida va TTA 2-klinikasida statsionar davolanayotgan kranioorbital shikastlangan 16 yoshdan 60 yoshgacha bo'lgan 62 nafar bemorni kompleks klinik ko'rikdan o'tkazish tahlili o'rganildi. **Natijalar va hulosa.** Bemorlarni har tomonlama tekshirish engil BMJ bilan birlashtirilgan orbital shikastlanishda ko'rish organining patologiyasi mavjudligini istisno qilishga imkon berdi, bu sog'likka zararning og'irligini baholashda ob'ektiv yondashuvni ta'minlashi kerak. Kranioorbital shikastlanishning dastlabki davrida rekonstruktiv operatsiyalarni amalga oshirish ko'z olmasi xarakatchanligini buzilishlarning 98,4%, ko'z olmasining distopiyasi – 82,5%, diplopiya – 86,5% regressiyasiga va yaxshi kosmetik natijalarga erishishga imkon beradi.

### Iqtiboslik uchun:

Mirbabaeva F.A. Kranioorbital shikastlanishlar va ularning ko'ruv faoliyatlariga ta'siri. Ilg'or oftalmologiya. 2024;7(1):37-41.

Fractures of the zygomatic-orbital complex rank second in the incidence of damage after fractures of the lower jaw. They account for 16-25% of all injuries to the maxillofacial area and meet general injury trends: a constant increase in the number of victims, an increase in complex types of fractures, rejuvenation of the patient population, severity of the injury due to its compatibility [1,3]. Eliminating deformation of the zygomatic-orbital-maxillary complex poses the most difficult task due to the fact that such an important organ as the eye and the lacrimal duct system are located in close proximity to it. [2,4]. The scope of the ophthalmological examination of victims with orbital injuries plays a significant role in assessing the severity of visual impairment in injuries in this area. In clinical practice, «mild» forms of orbital wall fractures are not uncommon, in which there is no complex of main symptoms and a favorable functional outcome. However, a number of authors claim that the trauma of the eye socket with the involvement of the eyeball and its entire organs in the midst of all the trauma of a human skeleton accounts from 36 to 64% [1.5]. The level of binocular vision impairment in fractures of the lower orbital wall is especially high, and this is the most common type among all orbital fractures [3]. In this regard, the need for the active participation of ophthalmologists in the diagnosis and rehabilitation of patients with orbital fractures is emphasized by many researchers [1,2,4,].

**The purpose of the study** is to study visual impairment in patients with orbital wall fractures depending on their location.

**Material and methods.** The work is based on an analysis of a comprehensive clinical examination of 62 patients with kranioorbital injuries who were undergoing inpatient treatment in the Maxillofacial

Surgery departments of the dental clinic of the Tashkent State Dental Institute and the 2-clinic of the Tashkent Medical Academy. Among the patients studied, there were 46 men (74%) and 16 women (26%). The patients' ages ranged from 16 to 60 years, with an average age of  $39.8 \pm 5.8$  years. Isolated eye socket wall injuries occurred in 20 32.4%, combined injuries (school-orbital) in 42 67.4% patients. Combined orbital trauma included damage to the eyeball (32 patients), brain (TBI – 5 patients), ENT organs (nose – 5 patients). The damage to the organ of vision, in all the cases we studied, was unilateral. The sinuses were altered in almost all patients, as the orbital trauma complex included orbital wall fractures, and therefore sinus changes. In terms of duration, orbital injury was conditionally divided into early period injury (up to 1) months after injury) – 47 patients and late period injury (more than 1 month after injury) – 15 patients.

In order to prevent complications from the organ of vision during orbital fractures, ophthalmologists carried out a comprehensive assessment of ophthalmological status within 2 weeks to 3 months after the injuries received: standard methods - visometry, refractometry, tonometry, perimetry, biomicroscopy, binocular vision examination, ophthalmoscopy and special methods – ultrasound examination of the eyeball (A and B-method), scanning of orbital space, one of the high-precision modern methods for assessing the condition of the retina and optic nerve – optical coherence tomography (OCT) was also used. The scope of the ophthalmological examination depended on the severity of the patient's condition. Patients with clear consciousness were determined to have visual acuity and color vision according to Rabkin's tables, and perimetry and ophthalmoscopy were performed.

Patients with conscious depression to moderate and deep stunning had their visual acuity checked using a manual Roseblum table, and their perimetry was brought in using a control method. Patients with depression of consciousness to the point of sopor and coma underwent only ophthalmoscopy.

The criterion for excluding OCT was concomitant severe injury to other organs, including moderate and severe TBI (severe and moderate brain contusion, intracranial hematomas, penetrating fractures of the vault and base of the skull).

Research results. Injuries were received during the attack, in a fight, from punches and kicks, as a result of falls, car injuries, etc. In all cases of orbital fracture, the injury was blunt an object of sufficient density.

The most typical complaint for patients with orbital trauma was the double vision of the objects in question: permanent or when looking to the sides.

On external examination, the position of the eye on the injured side was correct in 29 patients. The remaining eyes were shifted: in 18 patients downwards, exophthalmos without displacement of the eyeball was observed in 5 patients, enophthalmos – in 10 patients. In the patients we examined, the width of the palpebral fissure ranged from 6 to 12 mm and averaged  $10 \pm 1.6$  mm.

A clinical sign characterizing the severity of post-traumatic damage in the orbit is a violation of the mobility of the eyeball in a deformed orbit, developing as a result of damage to the motor nerves, either as a result of muscle infringement in the fracture area, or due to a decrease in functional activity in muscle hematomas.

We identified oculomotor disorders in 25 (41.9%) patients, eyeball dystopia – 18 (29.0%) patients. Impaired mobility of the eyeball and its position in orbit in 18 29.0% patients caused diplopia.

In case of violation of oculomotor technology, the limitation of the mobility of the eyeball was determined by 4 main (up, down, out, inward) and 4 intermediate meridians. During the examination, the most common mobility disorders were upward – 4 (16%) and combined forms – 1 (14.3%). The type of dystopia of the eyeball in patients with acute TBI was exophthalmos. It was defined in 5 patients, representing 8.06% of all patients and 27.77% of all eyeball dystopias.

An ultrasound examination of the orbit revealed signs of oculomotor muscle contusion in 8 12.8% patients, such as increased thickness and heterogeneity of their echostructure.

Analysis of the visometry data showed that visual acuity was not altered in 8 12.9% patients. Visual acuity (with maximum correction) of 1.0 was observed in 42 (67.7%) patients, visual acuity 0.7–0.9 in 7 (11.3%) patients, visual acuity 0.5–0.6 in 5 (8.1%) patients. However, we found that low visual acuity rates in all cases were associated with the presence of concomitant pathology of the visual organ not

associated with injury: initial cataracts, dystrophic changes in the retina and vitreous body caused by high myopia, as well as age-related macular degeneration. It should be noted that subjectively 29 (46.8%) patients noted a decrease in vision in the first hours (days) after injury, however, at the time of a comprehensive ophthalmological examination (term after injury from 2 weeks to 3 months), only 8 (12.9%) patients.

The main cause of visual impairment was the presence of traumatic optical neuropathy. Of the 62 patients, traumatic optic neuropathy was identified in 14 22.6% patients. Often the only ocular disorder of traumatic optic neuropathy was a relative afferent pupillary defect. The second cause of visual impairment was contusions of the eyeball of varying severity (58.8%). Mild concussions were detected in 42.5% of observations, moderate – in 48.1%, severe – in 9.4%.

Ophthalmoscopy revealed changes in the fundus pattern in 25 (40.3%) patients. Traumatic angioretinopathy was diagnosed in 14 (22.58%) patients, optic disc edema due to compression – in 5 (8.1%), anterior ischemic neuropathy – in 4 (6.5%), posterior ischemic neuropathy – in 2 (3.2%), Berlin retinal opacity – in 1 (1.6%) patient.

Perimetry and peripheral visual field changes were identified in 7 (11.3%) patients, of which 1 (14.5%) had traumatic optic neuropathy.

Intraocular pressure in all patients was within normal values and averaged  $17.5 \pm 1.3$  mmHg. When studying the parameters of hydrodynamics, it was found that in all patients the intraocular fluid secretion rate and Becker coefficient were within normal values.

A study of the morphometric parameters of the retina and optic nerve using the OCT method showed that the thickness of the retina in three regions of – fovea, parafovea, perifovea, as well as the condition of the retinal nerve fiber layer (RNF) in the majority of patients (70%) corresponded to the norm, in 13 (20.9%) patients had deviations of 1–2 indicators, and in 6 (9.6%) cases – deviations of more than two indicators. In all cases, deviations were minor.

All patients received complex conservative therapy, including corticosteroid, hemolytic, antibacterial, nootropic, neuroprotective, antioxidant and microcirculation-improving drugs, vitamin therapy, physiotherapy (Burgignon electrophoresis) from the 2–th week of the onset of the disease, a set of exercises for extraocular muscles, and massage of the eyeballs.

Surgical treatment - orbital wall reconstruction was performed in 47 (77%) patients. Closed reduction of the zygomatic bone with Limberg hook fixation was performed in a 30 (62.5%) displaced zygomatic fracture in patients, reconstructive interventions, with combined implants in 14 (39.1%) patients. If indicated, plastic surgery of the orbital walls was performed using a titanium plate and a mini plate with a mesh of 4 (8.3%) for patients (Figure 1).

In patients with severe TBI and severe co-injury, reconstructive surgeries were performed in a delayed

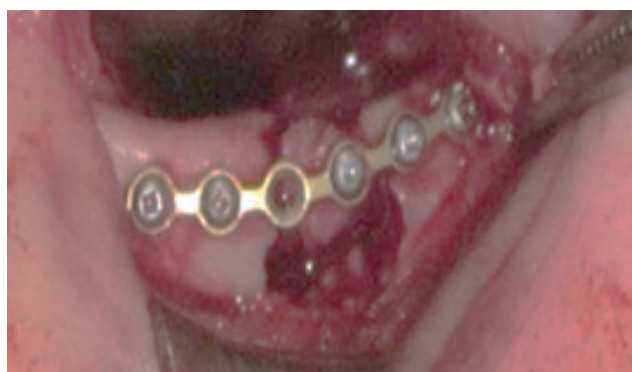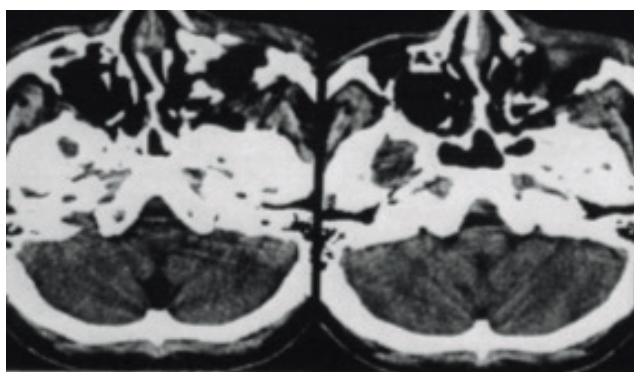


Fig.1. Condition during the titanium plate installation operation.

period, after stabilization of the condition. In stable patients, operations were performed in the first two days in 27 (56.2%) victims, up to 7 days – in 8 (16.6%), up to 14 days – in 10 (20.9%) and after two weeks or more – in 3 (6.25%) patients (Figure 2).

**Discussion.** As a result of reconstructive operations, by the time of discharge, the position of the eye was restored in whole or in part in 60 (96.7%), which amounted to 81.3% of the number of operated patients, oculomotor disorders regressed in 61 (98.4%) patients, which is 83.9% of the number of operated patients.

Visual functions in patients with craniorbital injuries were fully restored in 70.5% ( $p < 0.05$ ) of

dystopia of the eyeball, oculomotor disorders and diplopia.

2. A comprehensive ophthalmological examination of patients using traditional and special methods makes it possible to exclude the presence of pathology of the organ of vision in the combination of mild traumatic brain injury with orbital injury, which should provide an objective approach to the qualification of severity.
3. Carrying out reconstructive operations in the early period of craniorbital injury allows you to achieve regression of oculomotor disorders in 98.4% ( $p < 0.05$ ), dystopia of the eyeball – in

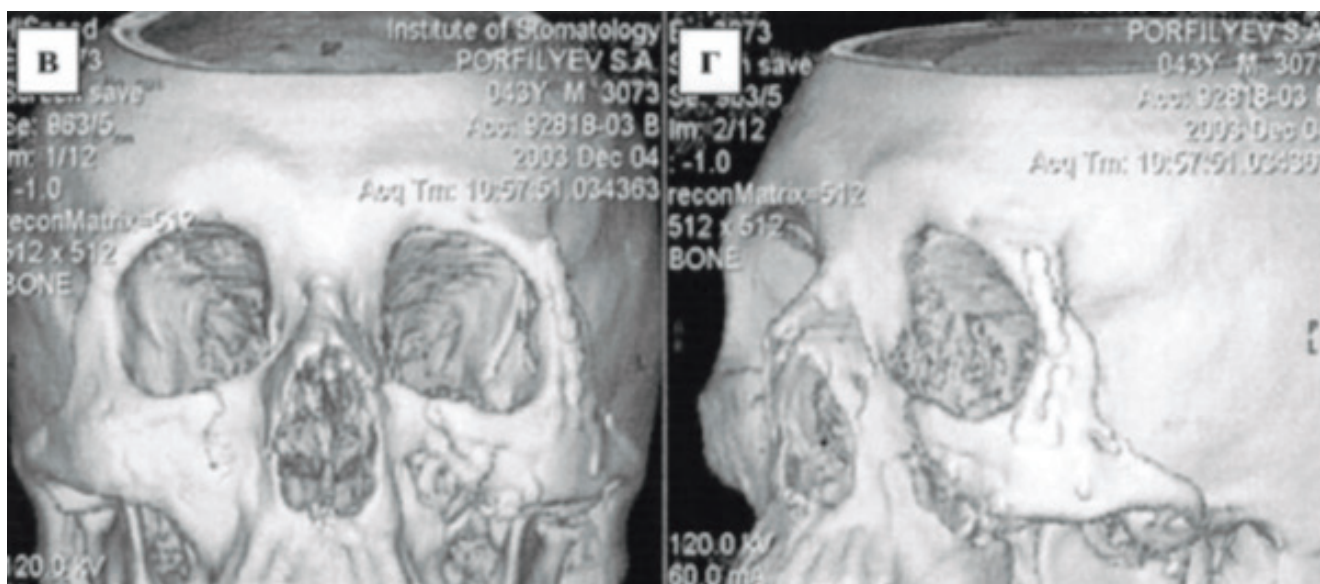


Fig. 2. Same patient 4 months after surgery. Three-dimensional reconstruction of the facial skull SCT image in direct (c) and oblique (d) projections. The integrity of the orbital ring has been restored with titanium miniplates)

patients, partially – in 25.1%.

**Conclusions.**

1. The main ophthalmological symptoms in orbital injury, which have resulted in a persistent loss of general ability to work, are

82.5% ( $p < 0.05$ ), diplopia – in 86.5% ( $p < 0.05$ ) and get good cosmetic outcomes.

**LITERATURE**

1. Гундорова Р.А., Нероев В.В., Кашников В.В. Травмы глаза. – М.: ГЕОТАР-Медиа, 2009. – С. 560.
2. Гундорова Р.А., Капелюшникова Н.И. Структура глазного травматизма. // Новые технологии в пластической хирургии придаточного аппарата глаза и орбиты в условиях чрезвычайных ситуаций и катастроф: материалы науч.-практ.конф. – М., 2007. – С. 152–154.
3. Мошетова Л.К., Кочергин С.А., Кутровская Н.Ю., Левченко О.В., Шалумов А.З., Хамидова Л.Т. Офтальмологическая диагностика и лечение краниоорбитальных повреждений в остром периоде черепно-мозговой травмы. – //Клиническая офтальмология. № 3.Том 10, 2009. - С. 89-93.
4. Николаенко В. П., Астахов Ю. С. Эпидемиология и классификация переломов нижней стенки орбиты//Офтальмологические ведомости. № 2.Том II. 2009. - С 56-70.
5. Siritongtaworn P, Tongsawas S., Siltharm S. Diplopia in facial fractures // J. Med. Assoc. Thai.. –Vol. 84, suppl. 2. 2001. – P. 491–494.