DOI: https://doi.org/10.57231/j.ao.2023.1.1.056 УДК: 617.7:616–008.6–005.4

THE CASE OF NEUROCHORIORETINITIS IN HIV–INFECTED PATIENT

Yusupov A. A.[1], Karimova M.Kh.,[2] Makhkamova D. K.,[3] Ashirmatova H. S.,[4] Bazarbaeva K. G.[5]

[1]DSc, Associate Professor, Director of Republican Specialized Scientific-Practical Medical Center of Eye Microsurgery
[2]DSc, Professor, Deputy Director of Republican Specialized Scientific-Practical Medical Center of Eye Microsurgery
[3]DSc, Republican Specialized Scientific-Practical Medical Center of Eye Microsurgery
[4]PhD, Republican Specialized Scientific-Practical Medical Center of Eye Microsurgery
[5]Resident of Republican Specialized Scientific-Practical Medical Center of Eye Microsurgery

Abstract. Relevance. In this scientific work, we described the case of neurochorioretinitis in hiv-infected patient. A male patient T. M., 44 years old, came to our Center with the following symptoms in both eyes: blurred vision with floaters. According to the patient words, initial sign was a blurry vision in left eye, which was a five month ago. Moreover, he started noticing floaters in the left eye. testing for HIV infection showed a positive result, and therefore, this patient was referred for consultation and treatment with a virologist. Inflammatory conditions in the posterior segments of eyeball can be taken as an initial manifestation for common diseases, including HIV. Considering the above, in the diagnosis and treatment of inflammatory pathologies of the organ of vision, not only the anterior, but also the posterior segment the HIV-alertness of an ophthalmologist can contribute to the early diagnosis of the disease, thereby saving the life of the patient.

Keywords. HIV, AIDS, neurochorioretinitis, Optic coherence tomography.

For citation:

Yusupov A. A., Karimova M.Kh., Makhkamova D. K., Ashirmatova H. S., Bazarbaeva K. G. The case of neurochorioretinitis in hiv-infected patient. — **Advanced ophthalmology.** — 2023; 1(1):234-237.

СЛУЧАЙ НЕЙРОХОРИОРЕТИНИТА У ВИЧ-ИНФИЦИРОВАННОГО ПАЦИЕНТА

Юсупов А. А.,[1] Каримова М. Х.,[2] Махкамова Д. К.,[3] Аширматова Х. С.,[4] Базарбаева К. Г.[5]

[1] Доктор медицинских наук, доцент, Республиканский специализированный научно-практический медицинский центр микрохирургии глаза
[2] Доктор медицинских наук, Заместитель директора, Республиканский специализированный научно-практический медицинский центр микрохирургии глаза
[3] Доктор медицинских наук, Республиканский специализированный научно-практический медицинский центр микрохирургии глаза
[4] Кандидат медицинских наук, Республиканский специализированный научно-практический медицинский центр микрохирургии глаза
[5] Клинический ординатор, Республиканский специализированный научно-практический медицинский центр микрохирургии глаза

Аннотация. Актуальность. В данной научной работе мы описали случай нейрохориоретинита у ВИЧ-инфицированного пациента. Больной Т. М., 44 года, обратился в наш Центр с жалобами на снижение зрения обоих глаз. Из анамнеза, начальным признаком было незначительное снижение зрения в левом глазу, которое началось 5 месяцев назад. Проведение анализа на ВИЧ-инфекцию показало положительный результат, в связи с чем данный больной был направлен на консультацию и лечение к вирусологу. Воспалительные состояния в задних сегментах глазного яблока можно принять за начальное проявление обших заболеваний, в том числе ВИЧ. Учитывая изложенное, при диагностике и лечении воспалительных патологий органа зрения не только переднего, но и заднего отрезка ВИЧ-настороженность врача-офтальмолога может способствовать ранней диагностике заболевания, тем самым спасая жизнь пациента.

Ключевые слова. ВИЧ, СПИД, нейрохориоретинит, Оптическая когерентная томография.

Для цитирования:

Юсупов А. А., Каримова М. Х., Махкамова Д. К., Аширматова Х. С., Базарбаева К. Г. Случай нейрохориоретинита у вич-инфицированного пациента. — **Передовая Офтальмология.** — 2023; 1(1):234-237.

OIV INFEKTSIYASI BO'LGAN BEMORDA NEYROXORİORETINIT RIVOJLANISH KLINIK HOLATI

Yusupov A. A.[1], Karimova M.Kh.,[2] Makhkamova D. K.,[3] Ashirmatova H. S.,[4] Bazarbaeva K. G.[5]

[1] Tibbiyot fanlari doktori, dotsent, Respublika ixtisoslashtiriggan ilmiy-amaliy ko'z mikroxirurgiyasi tibbiyot markazi
[2] Tibbiyot fanlari doktori, direktor o'rinbosari Respublika ixtisoslashtiriggan ilmiy-amaliy ko'z mikroxirurgiyasi tibbiyot markazi
[3] Tibbiyot fanlari doktori, Respublika ixtisoslashtiriggan ilmiy-amaliy ko'z mikroxirurgiyasi tibbiyot markazi
[4] Tibbiyot fanlari nomzodi, Respublika ixtisoslashtiriggan ilmiy-amaliy ko'z mikroxirurgiyasi tibbiyot markazi
[5] Klinik rezident, Respublika ixtisoslashtiriggan ilmiy-amaliy ko'z mikroxirurgiyasi tibbiyot markazi

Annotatsiya. Dolzarbligi. Ushbu ilmiy ishda biz OIV bilan kasallangan bemorda neyroxorioretinit holatini tasvirlab berdik. Markazimizga 44 yoshli erkak bemor T.M. ikkala ko'zida ko'rishning xiralashishi bilan bilan keldi. Bemorning so'zlariga ko'ra, boshlang'ich belgisi chap ko'zning loyqa ko'rishi bo'lib, bundan besh oy oldin boshlamgan. OIV infektsiyasi uchun test ijobiy natija ko'rsatdi, bu bemor virusolog bilan maslahatlashish va davolanish uchun yuborildi. Ko'z olmasining orqa segmentlaridagi yallig'lanish holatlari keng tarqalgan kasalliklar, shu jumladan, OIV uchun dastlabki ko'rinish sifatida qabul qilinishi mumkin. Yuqoridagilarni hisobga olgan holda, ko'rish organining yallig'lanish patologiyalarini tashxislash va davolashda nafaqat oldingi, balki orqa segmentdagi yallig'lanish holatlari oftalmologning OIV-ogohligi kasallikning erta tashxislashga yordam beradi va shu bilan bemorlarning hayotini saqlab qoladi.

Kalit so'zlar. OIV, OITS, neyroxorioretinit, Optik kogerent tomografiya.

Iqtibos uchun:

Yusupov A. A., Karimova M.Kh., Makhkamova D. K., Ashirmatova H. S., Bazarbaeva K. G. Oiv infektsiyasi bo'lgan bemorda neyroxorioretinit rivojlanish klinik holati. — **Peredovaya Oftalmologiya.** — 2023; 1(1):234-237.

Relevance. Acquired immunodeficiency syndrome (AIDS) is a chronic, potentially life-threatening condition caused by the human immunodeficiency virus (HIV). Intraocular inflammation in patients with human immunodeficiency virus (HIV) infection is commonly due to infectious uveitis. Ocular lesions due to opportunistic infections (OI) are the most common and have been described extensively in the pre highly active antiretroviral therapy (HAART) era. The common disorders occurring in HIV-infected patients are Cytomegalovirus (CMV) retinitis, chorioretinitis and neuroretinitis, as an early manifestation in about 15–20% patients.

Nonetheless, optic manifestations related with HIV depends on the amount of CD4 lymphocyte. Where the latest count less than 50. The severity of onset directly related with the amount of given number. The process of inflammation in HIV mostly involves the posterior structures of eyeball.

Purpose of the study. To analyze the manifestations, main aspects of diagnosis in ocular disorders in a given patient.

Material and methods. A male patient T. M., born in 1978 (44 years old), came to the outpatient department of the Republican Specialized Scientific-Practical Medical Center of Eye Microsurgery with the following symptoms in both eyes: blurred vision with floaters. According to the patient words, initial sign was a blurry vision in left eye, which was a five month ago. Moreover, he started noticing floaters in the left eye. The patient underwent standard ophthalmic and specific research methods, which consists of visiometry, tonometry, perimetry, biomicroscopy, biomicro-ophthalmoscopy, optical coherence tomography with angiography, computed perimetry, GBT (General Blood Test), TORCH screen, HIV testing.

Results. Ophthalmic status: visus: OD — 1,0; OS — 0.06 does not correct, intraocular pressure: OD / OS = 11 / 12mm Hg.

Biomicroophthalmoscopy: OD: fundus — optic disc — a vertical oval shape, pale pink color, the boundaries are clear, physiological excavation of 0.2–0,3, about 16 vessels passing through the optic disc edge, caliber of arteries and veins unchanged, macular reflex preserved, retina on the periphery without any pathology. OS: fundus — optic disc — edematous and hyperemic, boundaries are not determined with sharp prominence to a vitreous body, undefinable physiological excavation, about 19 vessels passing through the optic disc edge, course and caliber of arteries and veins within the normal range, macular reflex preserved, on the periphery of retina there were plenty of hemorrhagic hearths and cotton wool spots.

During static computer perimetry in the right eye there is an extension of Blind Spot boundaries, while in the left eye there is a sharp decrease in photosensitivity throughout the retina and multiple scotomas of various sizes. In this case: OD — MD: –2.11 dB; PSD: 3.12 dB. OS — MD: –14.92 dB; PSD: 11.54 dB.

Optic coherence tomography showed: OD — no pathology. OCT — OS — Macula protrudes into the vitreous body 1,276 μm, lamellar separation of the outer nuclear and outer plexiform layers from the myoid and ellipsoid zones (fig 1). There are intraretinal cystic inclusions in the parafoveolar zone and local detachment of the neuroepithelium in the perifoveolar and parapapillary zones (fig 2). The pigment epithelium is heterogeneous. Optic disc excavation parameters,

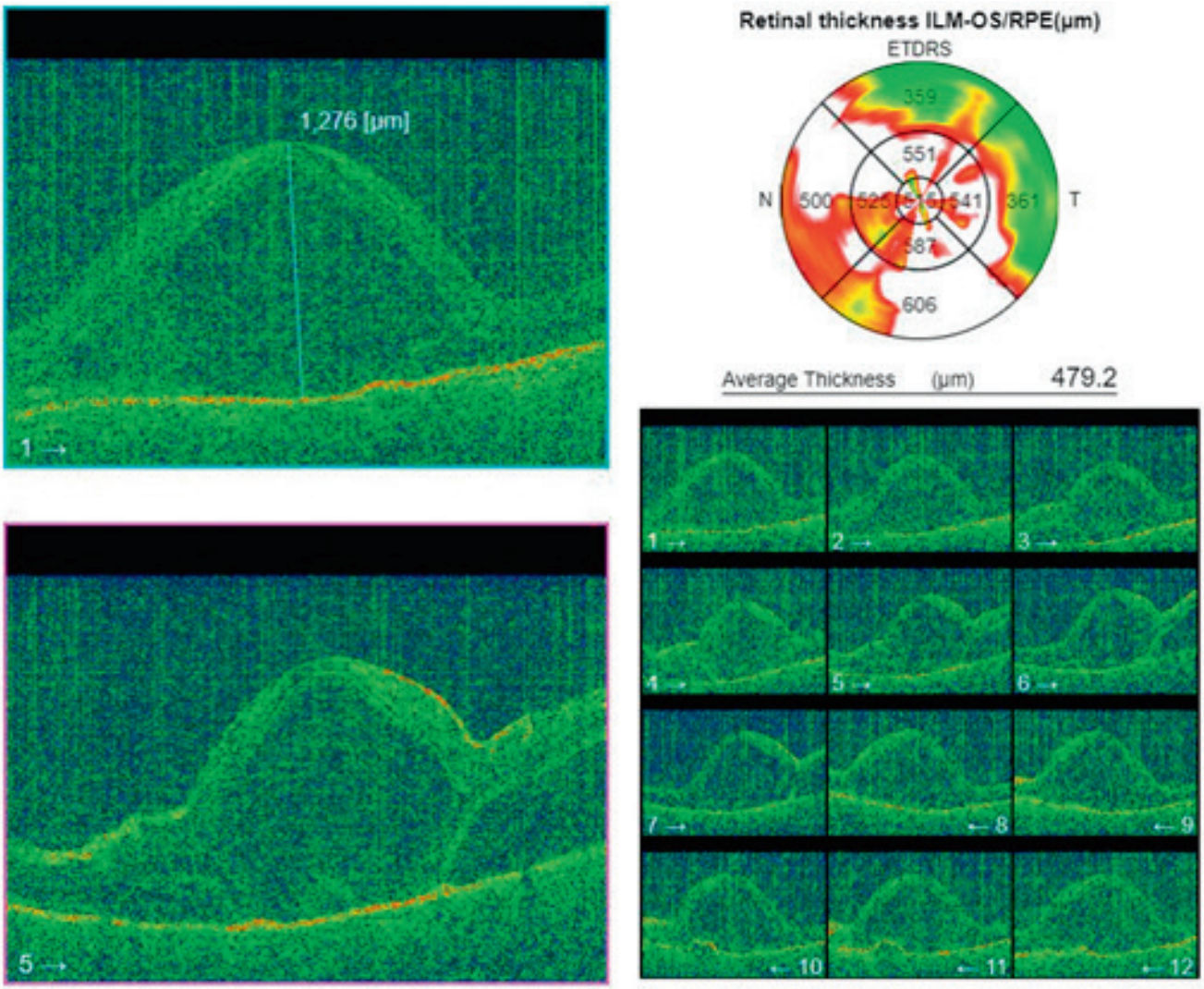

Figure 1. Optic coherence tomography of the left eye. It has showed lamellar separation of the outer nuclear and outer plexiform layers from the myoid and ellipsoid zones

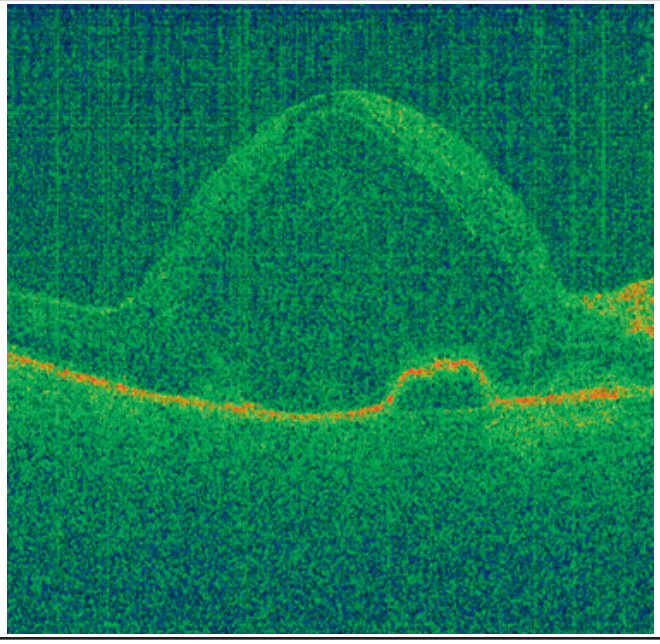

Figure 2. Optic coherence tomography of the left eye. It has showed local detachment of the neuroepithelium in the perifoveolar zone.

RNFL and GCL are overestimated due to media turbidity.

Testing for HIV infection showed a positive result, and therefore, this patient was referred for consultation and treatment with a virologist. Has been recommended antibiotics, anticoagulants, anti-inflammatory, decongestants locally and systemically, and antiretroviral therapy in order to prevent life threatening complications.

Conclusion. In the final analysis, inflammatory conditions in the posterior segments of eyeball can be taken as an initial manifestation for common diseases, including HIV. Considering the above, in the diagnosis and treatment of inflammatory pathologies of the organ of vision, not only the anterior, but also the posterior segment the HIV-alertness of an ophthalmologist can contribute to the early diagnosis of the disease, thereby saving the life of the patient.

REFERENCES

1. Holland GN, Gottlieb MS, Yee RD, Schanker HM, Pettit TH. Ocular disorders associated with a new severe acquired cellular immunodeficiency syndrome. Am J Ophthalmol. 1982;93:393–402.
2. Joshi RK, Mehendale SM. Determinants of consistently high HIV prevalence in Indian Districts: A multi-level analysis. PLoS One. 2019;14:216–321.
3. Holland GN. AIDS and ophthalmology: The first quarter century. Am J Ophthalmol. 2008;145:397–408.
4. Accorinti M, Pirraglia MP, Corradi R, Corsi C, Fabiani C, Pivetti-Pezzi P. Changing patterns of ocular manifestations in HIV seropositive patients treated with HAART. Eur J Ophthalmol. 2006;16:728–32.
5. Goldberg DE, Smithen LM, Angelilli A, Freeman WR. HIV-associated retinopathy in the HAART era. Retina. 2005;25:633–83.
6. Gottlieb MS, Schroff R, Schanker HM, Weisman JD, Fan PT, Wolf RA, et al. Pneumocystis carinii pneumonia and mucosal candidiasis in previously healthy homosexual men: Evidence of a new acquired cellular immunodeficiency. N Engl J Med. 1981;305:1425–31.
7. Barré-Sinoussi F, Chermann JC, Rey F, Nugeyre MT, Chamaret S, Gruest J, et al. Isolation of a T-lymphotropic retrovirus from a patient at risk for acquired immune deficiency syndrome (AIDS) Science. 1983;220:868–71.
8. Kestelyn PG, Cunningham ET., Jr HIV/AIDS and blindness. Bull World Health Organ. 2001;79:208–213.
9. Sudharshan S, Kaleemunnisha S, Banu AA, Shrikrishna S, George AE, Babu BR, et al. Ocular lesions in 1,000 consecutive HIV-positive patients in India: A long-term study. J Ophthalmic Inflamm Infect. 2013;3:2. 218–223